

**PATIENT**

Crowbar Cole

**SPECIES**

Canine

**BREED**

English Bulldog

**SEX**

Male Intact

**AGE**

6.18.11

**WEIGHT**

37.6lbs

**INTERPRETED BY**Maggie Machen Lamy,  
DVM, DACVIM  
(Cardiology)**HOSPITAL NAME**Fullerton Animal  
Hospital**REFERRING VET**

Dr. Unger

**INVOICE**

23929

**DATE**

4.28.22

**PRESENTING CLINICAL SIGNS**

History: Presented on 3/29/22 for weight loss. Not eating well, not interested in hard food. Drinking normal. Episode of collapse/hind end weakness. No v/d/s- Cough occasionally, hind end weakness. On exam decreased muscle mass along lumbar spine, 3lb weight loss, mm- pale pink, depressed, generalized dermatitis with crusts, otitis externa, KCS with mucoid discharge AU, abdomen potbellied-suspect free fluid, large skin tag caudal aspect LF, grade 2 heart murmur, ataxia in hind end Fast scan of ultrasound revealed free fluid. Had presented in 12/2021 for decreased appetite as well and increased respiratory effort. Normal CXR at that time.

-Pertinent abnormal PE/Chem/CBC/UA Results: Mild anemia, elevated ALP.

-Sedation used: Not required to complete full diagnostic ultrasound.

-Pertinent previous ultrasound results:

-STAT: Requested by DVM

-Imaging performed by: Andi Parkinson, RDMS

**ECHOCARDIOGRAM FINDINGS**

2D, m-mode, color flow and doppler imaging is available. The mitral valve appears mildly thickened, with no obvious prolapse into the left atrial lumen. Moderate MR. Decreased velocity. Severe left atrial dilation. Moderate LV dilation with increased sphericity and decline in myocardial function. Decreased LV wall thickness. The tricuspid valve appears mildly thickened in form and function. Mild RA/RV dilation. Moderate TR. Velocity consistent with mild pulmonary hypertension. The aortic valve is normal in morphology and mobility. No subvalvular ridge present; normal LVOT velocity with laminar flow. No aortic insufficiency. Normal pulmonic valve with no pulmonic insufficiency seen. A small uniform echogenicity tumor is seen associated with the aortic root (3.1 x 3.2cm) in best view cross section. No obvious chamber in position/compression is identified. Scant pericardial effusion noted. No pleural effusions seen.

**CARDIAC CHART**

CANINE CARDIAC PARAMETERS	MR VMAX (m/s)	TR VMAX (m/s)	LA/AO (Boon method)	LA/AO (Heart Base; Swe)	FS (%)	EF (%)	EPSS (cm)
NORMAL PARAMETER	4.5-5.5	<2.7	1.3	<1.6	28-40	40-100	<0.6
PATIENT	4.5	3.3	NM	2.0	16	34	NM
CANINE CARDIAC PARAMETERS	HR (BPM)	AV VMAX (m/s)	PV MAX (m/s)	BODY WEIGHT (kg)	LA 2D short axis Base view (cm)	LVIDd Avg; 2D and m-mode short axis (cm)	LVIDs Avg; 2D and m-mode short axis (cm)
NORMAL PARAMETER	50-100	0.7-1.7	0.7-1.6	BELOW	BELOW	BELOW	BELOW
PATIENT	277	NM	0.63	17.1	3.4	5.4	4.5
*Normal chamber parameters expressed as a mean value (SD)				3	1.27 (5.3)	2.46 (2.46)	1.36 (5.5)
<b>BODY WEIGHT DEPENDENT PARAMETERS</b>				5	1.40 (4.5)	2.74 (5.2)	1.60 (4.7)
<i>*Note: All measurements based upon multi-modal images and methods. An average value is reported.</i>				10	1.50 (3.8)	3.27 (3.5)	2.06 (3.1)
				15	1.83 (2.0)	3.71 (2.4)	2.43 (2.1)
				20	2.02 (1.9)	4.14 (2.2)	2.80 (2.0)
				25	2.18 (2.4)	4.48 (2.9)	3.10 (2.5)
				30	2.33 (3.3)	4.83 (3.9)	3.39 (3.4)
				35	2.48 (4.3)	5.17 (5.0)	3.69 (4.5)
				40	2.62 (5.2)	5.48 (6.1)	3.96 (5.4)
				50	2.88 (7.1)	6.07 (8.3)	4.46 (7.4)

Adapted from June Boon, Veterinary Echocardiography, 1998  
 Rishniw M and Hollis NE, J Vet Intern Med 2000; 14:429-435  
 Hansson et al, Vet Rad and Ultrasound 2002  
 Bonagura et al. Echocardiography: principles of interpretation, Vet Clin North Am 15:1177, 1995

## INTERPRETATION OF THE FINDINGS & FURTHER RECOMMENDATIONS

Unfortunately, this patient has four chamber dilation with a significant decline in systolic function. Moderate MR and TR are present as well, likely secondary to dilation; however, concurrent valve disease is not ruled out. The LA is severely enlarged, indicating risk for progression to CHF in the near future. The right heart is also affected, with mild RA/RV dilation and mild pulmonary hypertension. Additionally, a small mass is identified associated with the aortic root. This is likely a chemodectoma given the signalment; however, other tumor types cannot be ruled out. This is considered an incidental finding as no obvious chamber impingement or compression is visualized. It is important to note that particularly in this breed, it is difficult to evaluate peripheral vasculature and referral for a CT scan should always be considered (ie compression is possible). Finally, a small amount of pericardial effusion is noted, which likely reflects active congestion. The heart rate is significantly elevated, and an ECG is strongly recommended, as tachycardia-induced cardiomyopathy may also be present. No additional issues are identified in this study.

Dilation and dysfunction can be primary in nature (DCM) or develop to secondary to taurine deficiency, myocarditis, tachycardia-induced cardiomyopathy, hypothyroidism, or infiltrative disease such as lymphoma. Pending a full diet history, there is also concern for correlation with a non-traditional diet being fed in light of recent reports. A taurine level may be helpful as well, although supplementing taurine regardless of systemic levels is recommended as below (not all dogs with diet-related CM had abnormal taurine levels). Finally, further systemic evaluation for underlying infiltrative contribution such as neoplasia, thyroid panel, etc. is also reasonable (abdominal ultrasound, tick titers, etc.) although considered unlikely.

Based on today's findings in addition to the complaint of weakness/collapse, respiratory signs, etc. the dog is likely in early congestive heart failure and full cardiac support is recommended as below. If the patient appears unstable, hospitalization should be considered. Monitoring of sleeping breathing rates is recommended as the best way to screen for CHF in the future. Monitor for development of a murmur, cough, labored breathing, exercise intolerance or collapse episodes.

Prognosis is poor at this stage, given the onset of CHF with an average survival time of <6 months. If quality of life suffers, euthanasia should be considered. There will always be a risk for development of recurrent congestive heart failure, malignant arrhythmias (AF, VT), collapse and/or sudden death in the future.

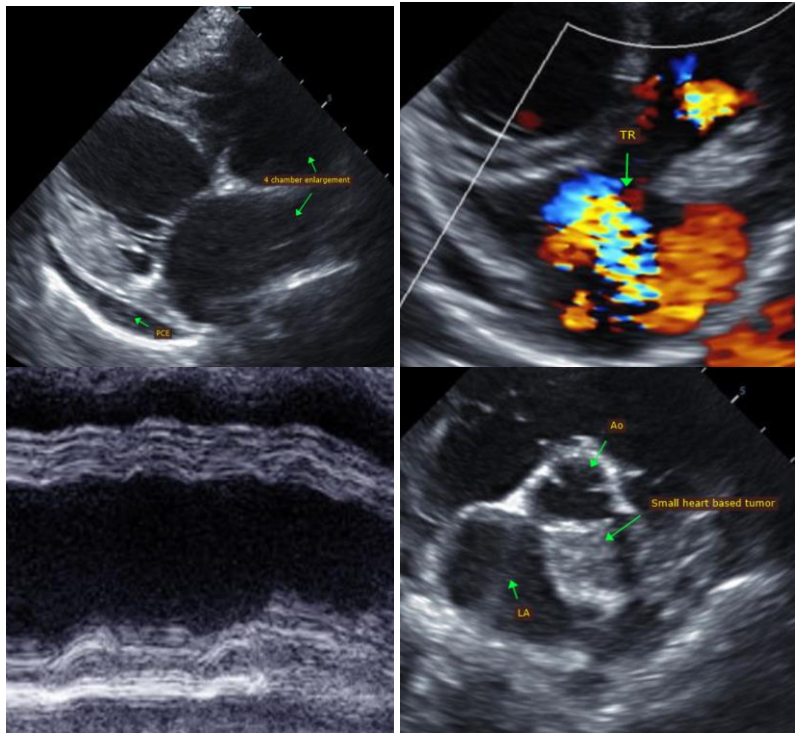
## PLAN

Consider baseline ECG and BP as discussed. Repeat CXR. Consider hospitalization if indicated. Institute Pimobendan (0.25-0.3mg/kg PO q12h). Institute spironolactone 1-2mg/kg PO q12h. Institute Lasix 1-2mg/kg PO q12h. Change to traditional diet as discussed. Submit taurine level if desired. Supplement taurine, 1000mg PO q8-12h. If BP is >130mmHg, institute ACEI 0.5mg/kg PO q12h. Consider further evaluation, such as diet history, thyroid testing, etc. as discussed. Referral for advanced imaging is recommended, particular should the patient be refractory to standard therapy.

A renal panel and BP are recommended in 1-2 weeks, then every 3-4 months lifelong to ensure tolerance of medications.

A recheck echocardiogram is recommended in 6 months, sooner if a murmur develops or any signs of cardiac disease are noted.

## IMAGES



The information and recommendations provided are based on the images presented by the referring veterinarian. No evaluation can be communicated regarding pathology that was not visible in the image/video clips provided.

Thank you for this referral. This report was generated using transcription software, and minor dictation errors may be present. If the clinical or image interpretation does not parallel your findings or if I can be of any further assistance, please contact me.

**Maggie Machen Lamy, DVM**  
Diplomate of the American College of Veterinary Internal Medicine (Cardiology)  
info@sonopath.com